

The Skull

Name: _____

PART A

Match the bones in column A with the features in column B. Place the letter of your choice in the space provided.

Column A	Column B
A. ethmoid bone	_____ 1. perpendicular plate
B. frontal bone	_____ 2. cribriform plate
C. occipital bone	_____ 3. crista galli
D. parietal bone	_____ 4. external auditory meatus
E. sphenoid bone	_____ 5. foramen magnum
F. temporal bone	_____ 6. mandibular fossa
	_____ 7. mastoid process
	_____ 8. middle nasal concha
	_____ 9. occipital condyle
	_____ 10. sella turcica
	_____ 11. styloid process
	_____ 12. supraorbital foramen (or notch)

PART B

Complete the following statements:

1. The _____ suture joins the frontal bone to the parietal bone.
2. The parietal bones are fused along the midline by the _____ suture.
3. The _____ suture joins the parietal bones to the occipital bone.
4. The temporal bones are joined to the parietal bones along the _____ sutures.
5. Name the three cranial bones that contain sinuses. _____

6. Name a facial bone that contains a sinus. _____

PART C

Match the bones in column A with the characteristics in column B. Place the letter of your choice in the space provided.

Column A	Column B
A. inferior nasal concha	_____ 1. forms bridge of nose
B. lacrimal bone	_____ 2. only movable bone in facial skeleton
C. mandible	_____ 3. contains coronoid process
D. maxillary bone	_____ 4. creates prominence of cheek below, and to side of, eye
E. nasal bone	_____ 5. contains sockets of upper teeth
F. palatine bone	_____ 6. forms inferior portion of nasal septum in back
G. vomer bone	_____ 7. forms anterior portion of zygomatic arch
H. zygomatic bone	_____ 8. scroll-shaped bone
	_____ 9. forms anterior roof of mouth
	_____ 10. forms posterior roof of mouth
	_____ 11. scalelike part in medial wall of orbit

Chapter 5. Skeletal System

9. Figure 5-3 (A-C) shows lateral, anterior, and inferior views of the skull. Select different colors for the bones listed below and color the coding circles and corresponding bones in the figure. Complete the figure by labeling the bone markings indicated by leader lines.

- | | | | |
|-----------------------------------|-----------------------------------|--|---|
| <input type="checkbox"/> Frontal | <input type="checkbox"/> Sphenoid | <input type="checkbox"/> Zygomatic | <input type="checkbox"/> Nasal |
| <input type="checkbox"/> Parietal | <input type="checkbox"/> Ethmoid | <input type="checkbox"/> Palatine | <input type="checkbox"/> Lacrimal |
| <input type="checkbox"/> Mandible | <input type="checkbox"/> Temporal | <input type="checkbox"/> Occipital | <input type="checkbox"/> Vomer |
| <input type="checkbox"/> Maxilla | | | |

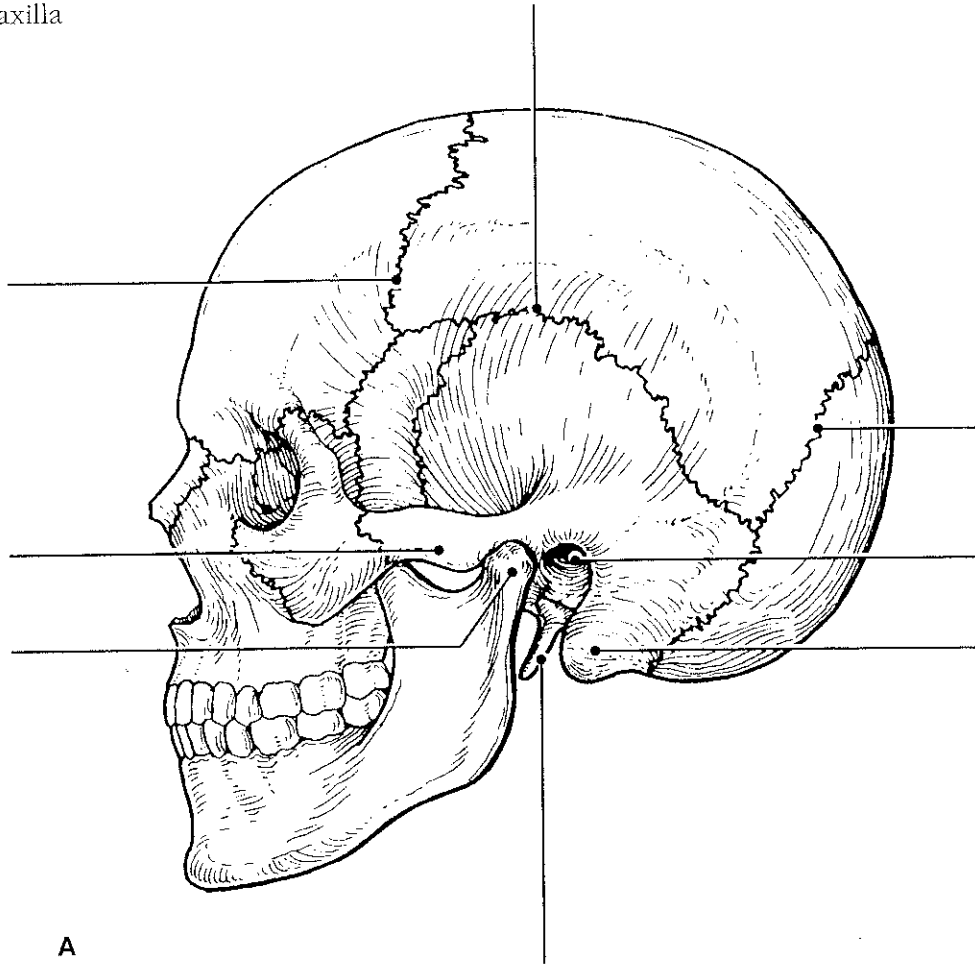
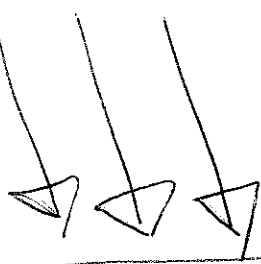


Figure 5-3, A-C



* For all diagrams: Label and color-code every bone.
 * Use the same color for every skull drawing.

Figure 12.4 Label the features of the floor of the cranial cavity.

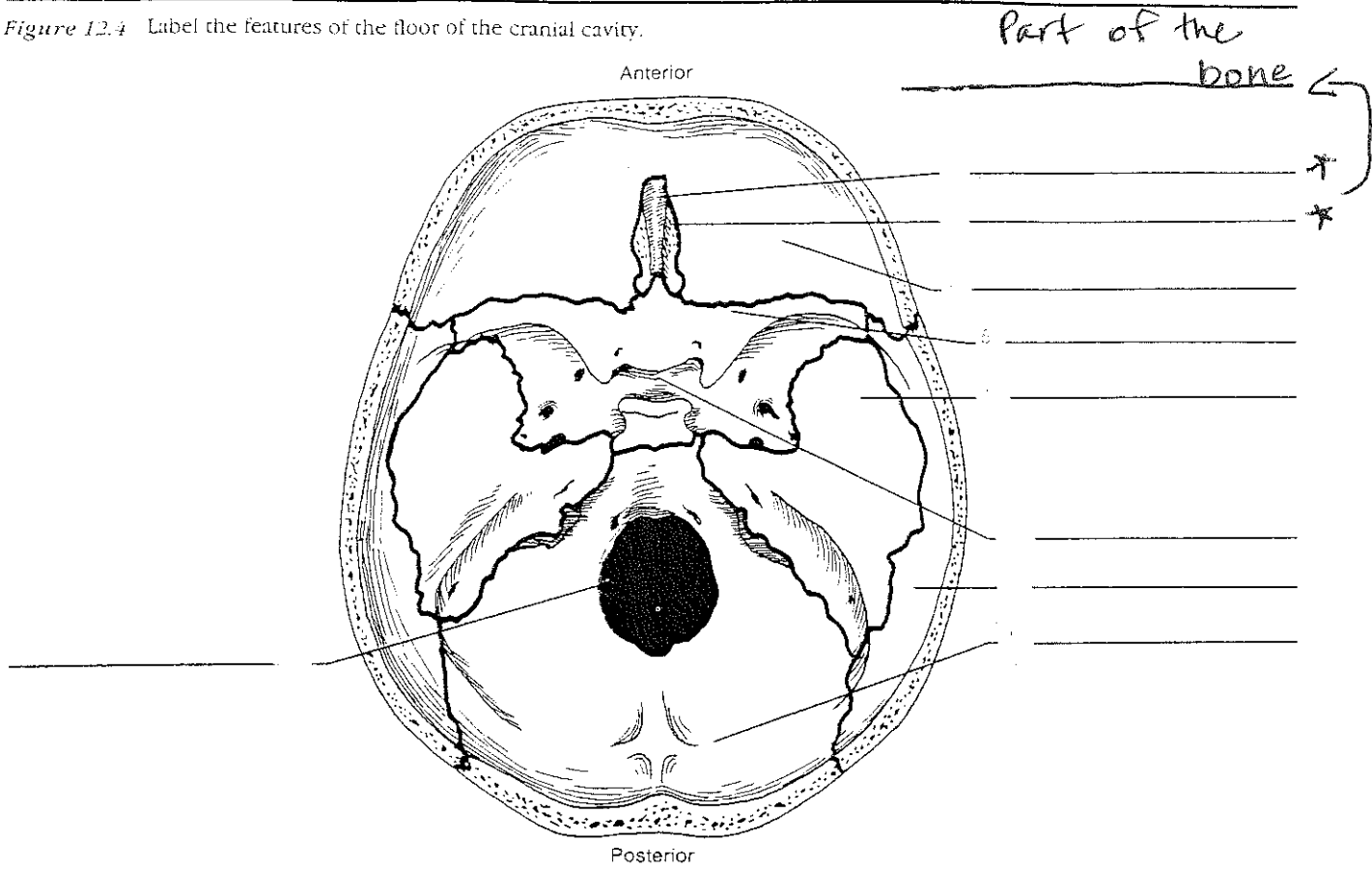
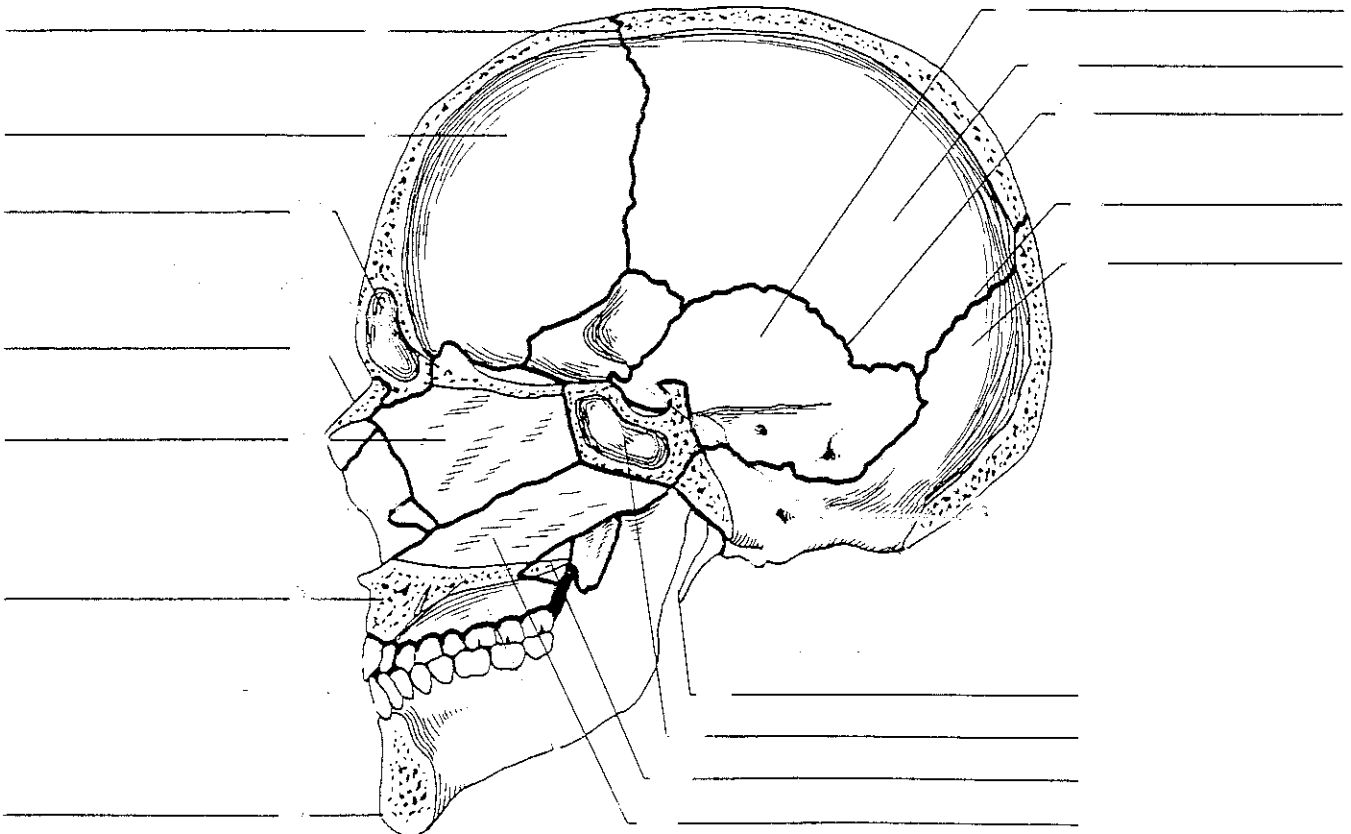
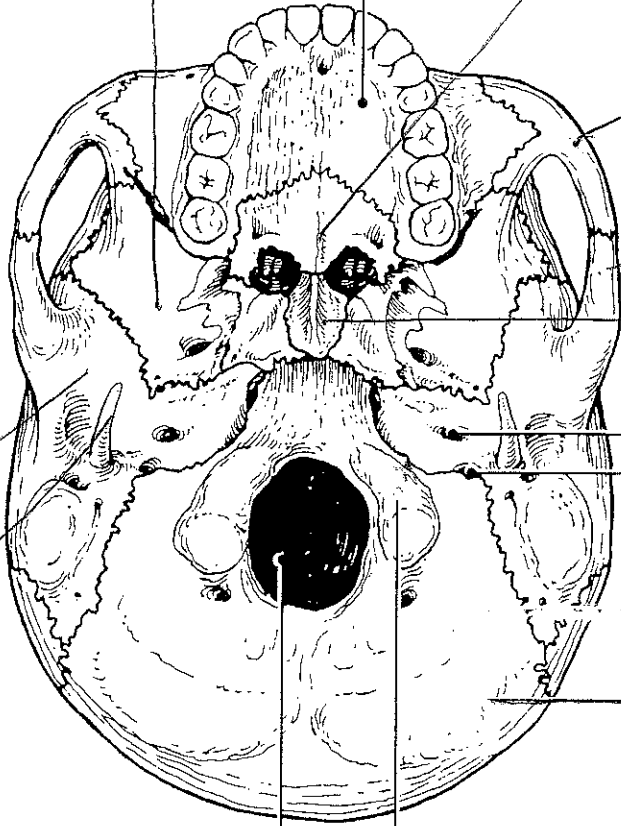


Figure 12.5 Label the features of the sagittal section of the skull.



B



C

