

The Skeleton

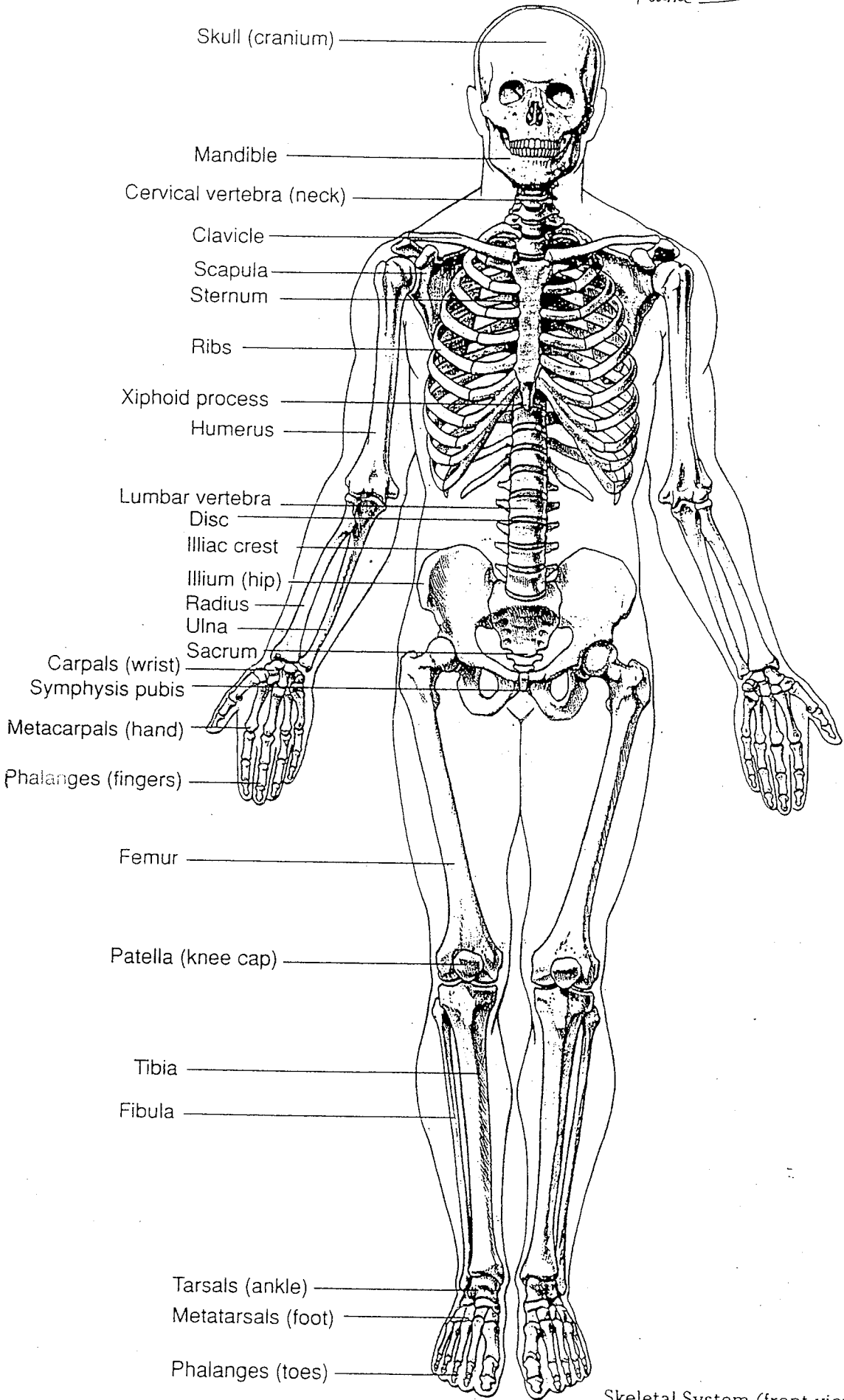
A. The AXIAL skeleton

1. Skull
2. Auditory Ossicles (Hammer, Anvil, Stapes)
3. Hyoid bone (pg. 202)
4. Vertebral Column – 33 vertebrae in the embryo fuse together to make 26 vertebrae at birth
 - 7 Cervical vertebrae (note – 1st/top vertebrae: **Atlas**, 2nd: **Axis**)
 - 12 Thoracic vertebrae
 - 5 Lumbar vertebrae
 - Sacrum (5 fused vertebrae)
 - Coccyx (4 fused vertebrae)
5. Thorax
 - Sternum
 - Ribs
 - True ribs – 7 pair attached to sternum directly via costal cartilage
 - False ribs – 3 pair attached to the 7th ribs, which are attached to the sternum
 - Floating ribs – 2 pair not attached to the sternum

B. The APPENDICULAR skeleton

1. Pectoral Girdle
 - 2 Scapulae
 - 2 Clavicles
2. Upper Limbs (2 Arms)
 - Humerus
 - Radius
 - Ulna
 - 8 Carpals form the Wrist
 - 5 Metacarpals form the Hand
 - 14 Phalanges form the Fingers
3. Pelvic/Hip Girdle
4. Lower limbs (2 Legs)
 - Femur
 - Patella
 - Tibia
 - Fibula
 - 7 Tarsals form the Ankle
 - 5 Metatarsals form the Foot
 - 14 Phalanges form the Toes

Name _____



Skeletal System (front view)